

Mass Mortality Attributed to Acanthocephaliasis at a Gull-billed Tern (*Gelochelidon nilotica*) Colony in Coastal California, USA

Author(s): Robert T. Patton, Katharine S. Goodenough, Susan E. W. De La Cruz, Hannahrose Nevins, Rebecca Cole, Barbara Bodenstein, Valerie Shearn-Bochsler, Brian Collins, Jessie Beck, Matthew Sadowski, and John Y. Takekawa
Source: Journal of Wildlife Diseases, 53(4):885-890.

Published By: Wildlife Disease Association

<https://doi.org/10.7589/2016-11-258>

URL: <http://www.bioone.org/doi/full/10.7589/2016-11-258>

BioOne (www.bioone.org) is a nonprofit, online aggregation of core research in the biological, ecological, and environmental sciences. BioOne provides a sustainable online platform for over 170 journals and books published by nonprofit societies, associations, museums, institutions, and presses.

Your use of this PDF, the BioOne Web site, and all posted and associated content indicates your acceptance of BioOne's Terms of Use, available at www.bioone.org/page/terms_of_use.

Usage of BioOne content is strictly limited to personal, educational, and non-commercial use. Commercial inquiries or rights and permissions requests should be directed to the individual publisher as copyright holder.

Mass Mortality Attributed to Acanthocephaliasis at a Gull-billed Tern (*Gelochelidon nilotica*) Colony in Coastal California, USA

Robert T. Patton,¹ Katharine S. Goodenough,^{2,3,8} Susan E. W. De La Cruz,⁴ Hannahrose Nevins,⁵ Rebecca Cole,⁶ Barbara Bodenstein,⁶ Valerie Shearn-Bochsler,⁶ Brian Collins,⁷ Jessie Beck,⁵ Matthew Sadowski,¹ and John Y. Takekawa³ ¹Avian Research Associates, 830 Orange Ave., Ste. K, Coronado, California 92118, USA; ²San Diego Waterbird Research Group, 4788-A West Mountain View Dr., San Diego, California 92115, USA; ³San Diego State University, Department of Biology, 5500 Campanile Dr., San Diego, California 92182, USA; ⁴US Geological Survey, Western Ecological Research Center, San Francisco Bay Estuary Field Station, 505 Azuar Dr., Vallejo, California 94592, USA; ⁵Marine Wildlife Veterinary Care and Research Center, California Department of Fish and Wildlife Office of Spill Prevention and Response, 1451 Shaffer Rd., Santa Cruz, California 95060, USA; ⁶US Geological Survey, National Wildlife Health Center, 6006 Schroeder Rd., Madison, Wisconsin 53711, USA; ⁷US Fish and Wildlife Service, San Diego Bay and Tijuana Slough National Wildlife Refuges, 301 Caspian Way, Imperial Beach, California 91932, USA; ⁸Corresponding author (email: kgoodenough@ou.edu)

ABSTRACT: From 12 May 2013 to 29 May 2013, the Gull-billed Tern (*Gelochelidon nilotica*) colony at the San Diego Bay National Wildlife Refuge, California, US, experienced a mass die-off of at least 92 adults, representing 71–92% of the breeding population on the US west coast. Cause of death was determined to be peritonitis due to perforations of the intestine by a large quantity of acanthocephala (*Profilicollis* [= *Polymorphus*] *altmani*). This is a unique report of *P. altmani* infecting *G. nilotica*, and a report of a great impact to a tern population in southern California. Mole crabs (*Emerita analoga*), the intermediate host for *P. altmani* and a major component of the Gull-billed Tern diet in San Diego, were found in the stomachs of necropsied terns along with cystacanths, and are the presumed source of the parasite infection. The tern's dietary reliance upon mole crabs likely amplified parasite transmission and infection. We suggest additional research to determine factors that influence parasite infection of intermediate and definitive hosts, particularly mole crabs, given that they are a vital resource for migrating birds within the coastal zone.

Key words: Acanthocephala, *Emerita analoga*, *Gelochelidon nilotica*, Gull-billed Tern, mole crab, parasite, *Profilicollis altmani*.

The western Gull-billed Tern (*Gelochelidon nilotica*) is a medium-sized migratory seabird considered a species of concern by federal and California state agencies (Molina et al. 2014). This tern has a restricted range extending from Southern California south along the Pacific coasts of Baja California and continental Mexico. The breeding population is estimated to be 800–1,050 breeding pairs in 9–12 small colonies (Molina et al. 2014).

Nesting was first confirmed in 1987 at the San Diego Bay National Wildlife Refuge (SDBNWR) with three breeding pairs in 1987 (Unitt 2004) and continued to increase to 65 breeding pairs in 2013.

In May 2013, the SDBNWR colony experienced a severe mortality event that resulted in the death of 71–92% of the San Diego breeding population. At the time of mortality, the breeding population was 130 terns with up to 20 additional terns present but not breeding. From 12 May to 29 May, we recovered 92 adult Gull-billed Tern carcasses from the breeding colony and other areas of SDBNWR, along beaches of the Tijuana Estuary, in Nestor, and in Chula Vista (Fig. 1). The shoreline of San Diego Bay and nearby beaches were searched on foot. Federal, state, and local officials were advised of the mortality and were asked to document observations of ill or deceased birds within San Diego County. We contacted researchers at other breeding colony locations to discover the breadth of the mortality, but only the SDBNWR Gull-billed Terns appeared to be affected.

All tern carcasses were recovered within 7 km of the breeding colony (Fig. 1). Only one brood survived the mortality event with both parents surviving and attending chicks. All remaining nests in the colony were subsequently abandoned (Fig. 2). Censuses conducted after the mortality indicated that 12 individuals likely survived the mortality event. None of the survivors were examined for

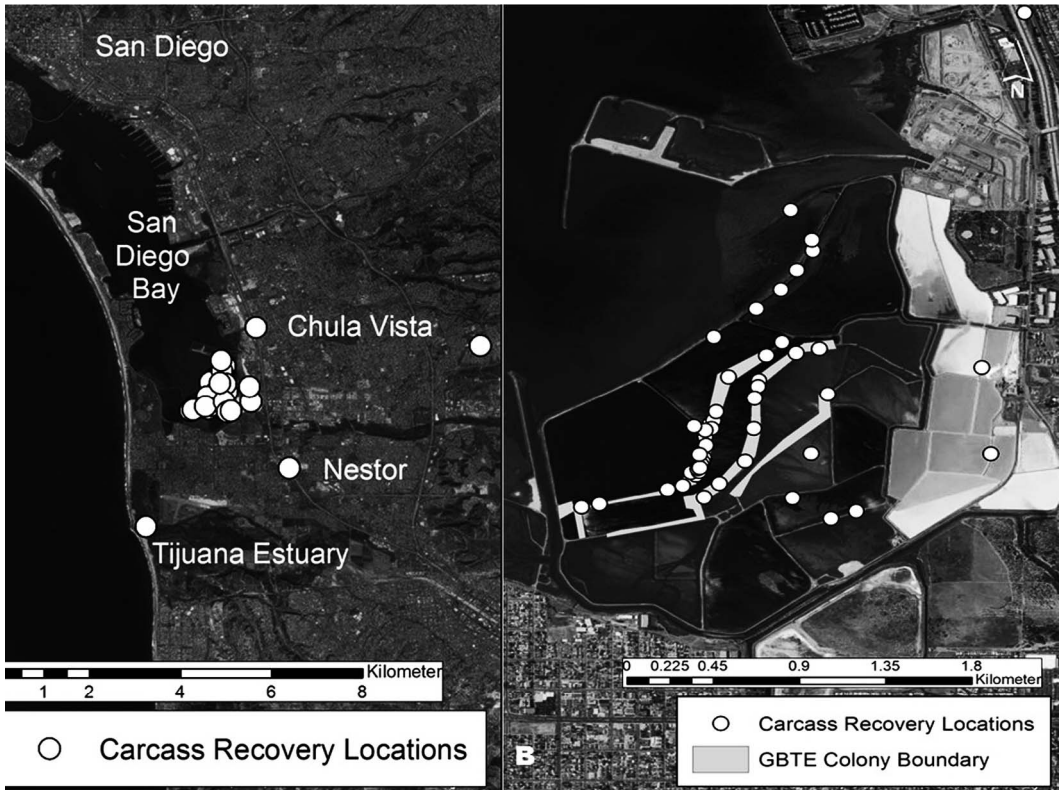


FIGURE 1. Maps depicting the location of the Gull-billed Tern (*Gelochelidon nilotica*) breeding colony and locations of the 2013 mortality in San Diego Bay, California, USA. (left panel) Map provides information on carcass detection throughout south San Diego County, San Diego. All carcasses were discovered within 7 km of the breeding colony. (B) A close-up view of the Gull-billed Tern (GBTE) breeding colony and locations of carcasses within San Diego.

infection after the mortality due to the difficulty of capture for this species. No mortality events of similar impact have been previously reported in Southern California.

As cause of death was not immediately apparent, four carcasses were sent to the US Geological Survey's National Wildlife Health Center (NWHC) in Madison, Wisconsin, for necropsy and testing (NWHC Case 24394-1-4). Three of the terns were necropsied while one was retained as a reference specimen. Results indicated that cause of death was peritonitis due to intestinal perforations by many acanthocephalans identified as (*Profilicollis* [= *Polymorphus*] *altmani*) with the use of morphological keys (Perry 1942; Amin 2013). Acanthocephalan proboscises and cystacanth stages were visible on the serosa of the

intestine and in the intestinal mesenteries. Adhesions were noted between loops of the intestine, and multifocal, marked, necrotizing, and granulomatous enteritis was seen on histopathology. In some foci, there were parasitic granulomas in the intestinal muscularis which extended through the serosal surface.

Two of the acanthocephalan infected terns had gastric nematodes (*Schistorophus* sp.), and one had renal trematodes (*Renicola* sp.), but infections were minimal and did not appear to have caused significant pathology. Routine bacterial culture, isolation, and identification were performed on lung and liver as described in Blehert et al. (2014). Attempts at viral isolation were performed as described in Ip et al. (2013). No significant bacterial or

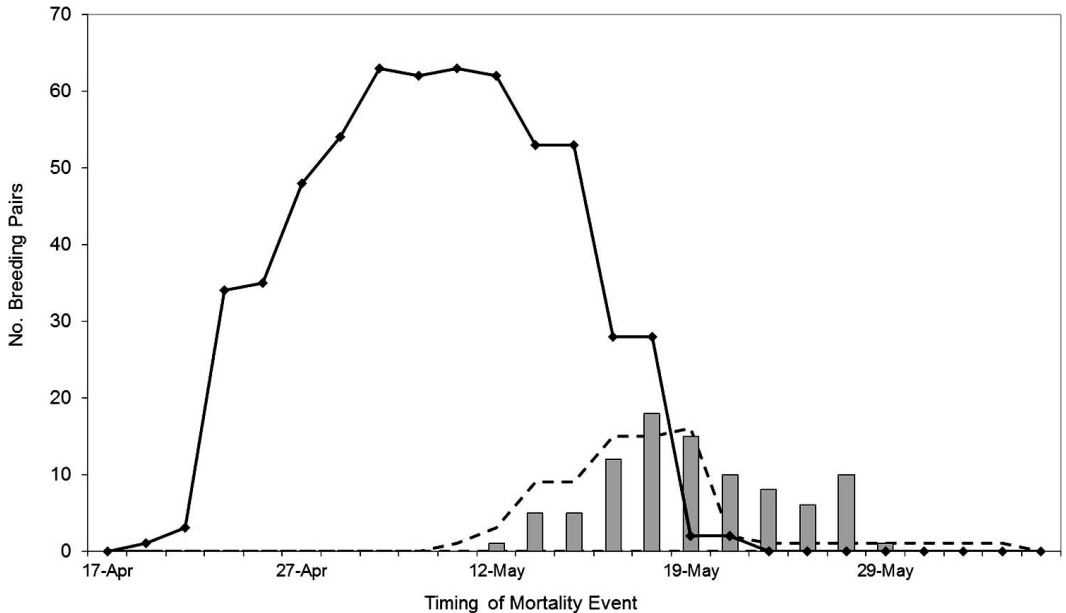


FIGURE 2. The chronology of Gull-billed Tern (*Gelochelidon nilotica*) breeding effort and mortality in South San Diego Bay, California, USA, in May 2013. The solid black line with diamond markers plots the number of concurrently active nests over time ($n=65$). The white area under the line indicates the number of broods present ($n=25$). The dark gray columns indicate the number of adult carcasses retrieved ($n=92$). Only one chick survived to successfully fledge and depart the breeding colony in 2013.

viral pathogens were detected in any of the terns examined.

In addition to the carcasses sent to NWHC, 45 carcasses were examined at other facilities: four at SeaWorld San Diego and 41 at the California Department of Fish and Wildlife, Marine Wildlife Veterinary Care and Research Center in Santa Cruz, California (MWVCRC). While there were additional carcasses of both adults and chicks, necropsies on these carcasses were limited due to poor postmortem conditions. Pathological assessments from SeaWorld and MWVCRC support the initial results from NWHC. Results of gross necropsy of adults sent to MWVCRC found the terns to be in a moderate to extreme state of emaciation. Although subcutaneous fat was severely depleted, pectoralis muscles were only mildly to moderately atrophied, suggestive of a short window of depletion of energy stores (days) rather than a prolonged event (weeks). Stomach contents of 35 terns contained one or two recently eaten mole crab (*Emerita analoga*) remains (Fig. 3). While

digestion rate for terns is not known, the decomposition of crab carapaces indicated they were likely consumed within the last day before death. The MWVCRC found one to eight cystacanths either within mole crab remains or free-floating in the ventriculi of 15 terns (36%).

Severe acanthocephalan infestations of the lower intestinal tract were observed in 34 of the 41 fully examined terns, although parasitic infection varied among different sections of the intestinal tract. No acanthocephalans were found in the duodenum, colon, caeca, or cloaca. Areas of infection in the jejunum and ileum were classified as low (less than 40% affected), moderate (between 40% and 60% affected), or severe (greater than 65% of the area affected). A majority (90%) of birds had moderate to severe infection in the jejunum with an average area affected of 70% (range: 20–100%). The ileum was similarly affected with an average affected area of 88% (range: 50–100%) and infection varied in severity from low (3), moderate (7), or severe (19)

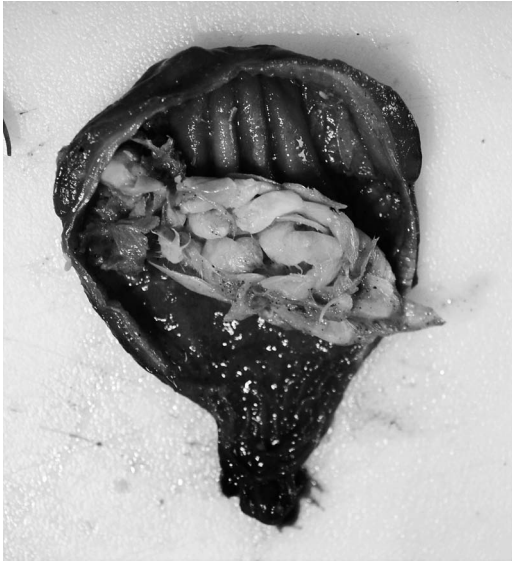

FIGURE 3. Mole crabs (*Emerita analoga*) discovered during necropsy in the stomach of a Gull-billed Tern (*Gelochelidon nilotica*) recovered during the 2013 mortality in San Diego Bay, California, USA. Digestion rates suggested mole crabs were consumed within 24 h before death of the bird.

infection ($n=29$). In the jejunum and ileum combined, the number of parasites ranged from 3 parasites/cm to 22 parasites/cm² (mean=7.4, SD=3.2). Voucher specimens of acanthocephalans were deposited at the Sam Noble Oklahoma Museum of Natural History (catalog nos. OMNH-217001, OMNH-217002, OMNH-217003).

Acanthocephalans are intestinal parasites that have a wide geographical distribution and can cause severe disease outbreaks and mortality in several species (Cole 1999). In food webs of North American Pacific Coast sandy beaches, two acanthocephalan species, *P. altmani* and *Proflicollis kenti*, have been implicated in mass die-offs involving Surf Scoters (*Melanitta perspicillata*; Kreuder et al. 2003) and southern sea otters (*Enhydra lutris nereis*; Mayer et al. 2003). Bird species from the family Laridae are also documented as definitive hosts (Latham and Poulan 2003; Dronen et al. 2007). *Proflicollis* spp. have indirect life cycles that include the Pacific mole crab (Reish 1950; Royal et al. 2004) as an

intermediate host. Bird species that have a crustacean component to their diet appear to be more vulnerable to *Proflicollis* spp. (Hanssen et al. 2003; Smith 2007).

Acanthocephalan eggs are spread along the intertidal zone of sandy beaches through bird feces, and mole crabs are infected by ingesting the eggs. The eggs hatch, releasing the acanthor, which penetrates tissues or moves into the hemocoel of the crab where it develops to the juvenile cystacanth stage. When infected crabs are eaten by birds, the cystacanths attach to the birds' intestines where they mature into dioecious adults. After mating, the female releases eggs into the bird's intestinal tract, resulting in dispersion of the eggs into the environment via feces (Reish 1950; Karl 1967; Schmidt 1985).

One factor that appeared to contribute to the intensity of the parasite infection of the Gull-billed Terns in San Diego was the importance of mole crabs to the terns' diet. The Gull-billed Tern is a dietary generalist that consumes a combination of aquatic and terrestrial food resources (Molina et al. 2014); however, in San Diego, mole crabs are a major component of the terns' diet, comprising greater than 70% of the adult diet (Good-enough 2014). Infected crabs have been documented to be slower at burrowing in the intertidal swash zone, thereby increasing predation risk to the crabs and increasing exposure to parasites by foraging terns (Kolluru et al. 2011).

Factors influencing recruitment and spatio-temporal distributions of acanthocephalans are not well understood, making it difficult to predict epizootics and their effects on wildlife (Hudson et al. 2002; Latham and Poulin 2003). However, understanding abiotic and biotic influences upon intermediate host distribution and abundance may be crucial to understanding patterns of parasite distributions (Valiela et al. 1992; Dugan et al. 1994; Goulding and Cohen 2014). We suggest additional research to better understand factors influencing intermediate and definitive host vulnerability and parasite

movement within the coastal beach community.

We thank Judy St. Leger and the veterinary staff at SeaWorld San Diego, the veterinary staff at California Department of Fish and Wildlife Marine Wildlife Veterinary Care and Research Center, and Mauritz Sterner III of the US Geological Survey National Wildlife Health Center for assistance with parasite identification; and personnel from the San Diego Bay National Wildlife Refuge and South Bay Salt Works, and Lesley Handa, Lea Squires, and Charles Gailband for their assistance with collecting carcasses. Photos were provided courtesy of the Marine Wildlife and Veterinary Care and Research Center. Use of trade, product, or firm names does not imply US government endorsement.

LITERATURE CITED

- Amin OM. 2013. Classification of the acanthocephala. *Folia Parasitol (Praha)* 60:273–305.
- Bleher DS, Maluping RP, Green DE, Berlowski-Zier BM, Ballmann AE, Langenberg JA. 2014. Acute pasteurellosis in wild big brown bats (*Eptesicus fuscus*). *J Wildl Dis* 50:136–139.
- Cole RA. 1999. Acanthocephaliasis. In: *Field manual of wildlife diseases: General field procedures and diseases of birds*, Friend M, Franson JC, editors. *Information and Technology Report 1999-001*, US Geological Survey, Biological Resources Division, National Wildlife Health Center, Madison, Wisconsin, pp. 241–243.
- Dronen NO, Blend CK, Gardner SL, Jiménez FA. 2007. *Stictodora cablei* n. sp. (Digenea: Heterophyidae) from the royal tern, *Sterna maxima* (Laridae: Sterninae) from Puerto Rico and the Brazos County area of the Texas Gulf coast, U.S.A., with a list of other endohelminths recovered in Texas. *Zootaxa* 1432:35–56.
- Dugan JE, Hubbard DM, Wenner AM. 1994. Geographic variation in life history of the sand crab, *Emerita analoga* (Stimpson) on the California coast: Relationships to environmental variables. *J Exp Mar Biol Ecol* 181:255–278.
- Goodenough KS. 2014. *Gull-billed Tern, Gelochelidon nilotica, inter- and intra-annual variation in movements and diet in San Diego, California*. MS Thesis, Biology Department, San Diego State University, San Diego, California, 44 pp.
- Goulding TC, Cohen CS. 2014. Phylogeography of a marine acanthocephalan: Lack of cryptic diversity in a cosmopolitan parasite of mole crabs. *J Biogeogr* 41: 965–976.
- Hanssen SA, Folstad I, Erikstad KE, Oksanen A. 2003. Costs of parasites in common eiders: Effects of antiparasite treatment. *Oikos* 100:105–111.
- Hudson PJ, Rizzoli A, Grenfell BT, Heesterbeek H, Dobson AP, editors. 2002. *The ecology of wildlife diseases*. Oxford University Press, Oxford, UK, 197 pp.
- Ip HS, Van Wettere AJ, McFarlane L, Shearn-Bochsler V, Dickson SL, Baker J, Hatch G, Cavender K, Long R, Bodenstern B. 2013. West Nile virus transmission in winter: The 2013 Great Salt Lake Bald Eagle and Eared Grebes mortality event. *PLoS Curr* 6:currents.outbreaks.b0f031fc8db2a827d9da0f30f0766871.
- Karl JE Jr. 1967. *Studies on the systematics and life history of Polymorphus altmani (Perry)*. PhD Dissertation, Department of Zoology and Physiology, Louisiana State University, Baton Rouge, Louisiana, 144 pp.
- Kolluru GR, Green ZS, Vredevoe LK, Kuzma MR, Ramadan SN, Zosky MR. 2011. Parasite infection and sand coarseness increase sand crab (*Emerita analoga*) burrowing time. *Behav Process* 88:184–191.
- Kreuder C, Miller MA, Jessup DA, Lowenstine LJ, Harris MD, Ames JA, Carpenter TE, Conrad PA, Mazet JKA. 2003. Patterns of mortality in southern sea otters (*Enhydra lutris nereis*) from 1998–2001. *J Wildl Dis* 39:495–509.
- Latham AD, Poulin R. 2003. Spatiotemporal heterogeneity in recruitment of larval parasites to shore crab intermediate hosts: the influence of shorebird definitive hosts. *Can J Zool* 81:1282–1291.
- Mayer KA, Dailey MD, Miller MA. 2003. Helminth parasites of the southern sea otter *Enhydra lutris nereis* in central California: Abundance, distribution and pathology. *Dis Aquat Org* 53:77–88.
- Molina KC, Parnell JF, Erwin RM. 2014. *Gull-billed Tern (Gelochelidon nilotica)*. In: *The birds of North America online*, Poole A, editor. Ithaca, NY, Cornell Lab of Ornithology. <http://bna.birds.cornell.edu.bnaproxy.birds.cornell.edu/bna/species/140>. Accessed June 2014.
- Perry ML. 1942. A new species of the acanthocephalan genus *Filicollis*. *J Parasitol* 28:385–388.
- Reish DJ. 1950. Preliminary note on the life cycle of the acanthocephalan, *Polymorphus kenti* Van Cleave, 1947. *J Parasitol* 36:496.
- Royal L, Dailey M, Demaree R, Sakanari J. 2004. Acanthocephala cystacanth infections in sand crabs from Bodega Bay, California. *Calif Fish Game* 90:36–41.
- Schmidt GD. 1985. Development and life cycles. In: *Biology of the acanthocephala*, Crompton DWT, Nickol BB, editors. Cambridge University Press, New York, New York, pp. 273–306.
- Smith NF. 2007. Associations between shorebird abundance and parasites in the sand crab, *Emerita analoga*, along the California coast. *J Parasitol* 93: 265–273.

Unitt P. 2004. San Diego County bird atlas. *Proceedings of the San Diego Society of Natural History*, No. 39. Ibis Publishing, Temecula, California, 645 pp.

Valiela I, Foreman K, LaMontagne M, Hersh D, Costa J, Peckol P, DeMeo-Anderson B, D'Avanzo C, Babione M, Sham CH, et al. 1992. Couplings of watersheds and coastal waters: Sources and consequences of

nutrient enrichment in Waquoit Bay, Massachusetts. *Estuaries* 15:443–457.

Submitted for publication 15 November 2016.

Accepted 28 March 2017.